

CONTRAST-ENHANCED ULTRASOUND IN OVARIAN TUMORS – DIAGNOSTIC PARAMETERS: METHOD PRESENTATION AND INITIAL EXPERIENCE

ANITA-ROXANA MAXIM¹, RADU BADEA², ATILLA TAMAS²,
ALEXANDRU TRAILA³

¹Department of Obstetrics and Gynaecology, Iuliu Hațieganu University of Medicine and Pharmacy, Cluj-Napoca, “Dominic Stanca” Clinic Cluj-Napoca, Romania

²Department of Medical Imaging, Iuliu Hațieganu University of Medicine and Pharmacy Cluj-Napoca, Regional Gastroenterology and Hepatology Institute “Prof. Dr. Octavian Fodor” Cluj-Napoca, Romania

³Department of Oncologic Surgery, Oncology Institute “Prof. Dr. I. Chiricuță” Cluj-Napoca, Romania

Abstract

The aim of this paper is to discuss and illustrate the use of contrast-enhanced ultrasound in evaluating ovarian tumors compared to conventional ultrasound, Doppler ultrasound and the histopathological analysis and suggest how this technique may best be used to distinguish benign from malignant ovarian masses.

We present the method and initial experience of our center by analyzing the parameters used in contrast-enhanced ultrasound in 6 patients with ovarian tumors of uncertain etiology. For examination we used a Siemens ultrasound machine with dedicated contrast software and the contrast agent SonoVue, Bracco. The patients underwent conventional ultrasound, Doppler ultrasound and i.v. administration of the contrast agent. The parameters studied were: inflow of contrast (rise time), time to peak enhancement, mean transit time.

The series of patients is part of an extensive prospective PhD study aimed at elaborating a differential diagnosis protocol for benign versus malignant ovarian tumors, by validating specific parameters for contrast-enhanced ultrasound.

Although the method is currently used with great success in gastroenterology, urology and senology, its validation in gynecology is still in the early phases. Taking into consideration that the method is minimally invasive and much less costly than CT/MRI imaging, demonstrating its utility in oncologic gynecology would be a big step in preoperative evaluation of these cases.

Keywords: contrast-enhanced ultrasound, ovarian tumor, contrast parameters.

Introduction

Ovarian cancer is responsible for the highest death rate among gynecological cancers and is the 5th most frequent malignancy in female patients. Worldwide, approximately 200,000 women are diagnosed with this pathology and more than half will die in spite of new surgical and chemotherapeutic protocols available [1]. More than 90% of cases are epithelial tumors, including borderline masses. Epithelial ovarian cancer is unique compared to

other solid malignant tumors, in that it originates at the surface epithelium rather than the parenchymatous area of the organ. The rest of the 10% originate either in the germinative ovarian cells or are stromal tumors [2].

The global risk for a patient to develop ovarian cancer throughout their lifetime is 1.8% [2]. There is no effective screening method and the clinical presentation is scarce and non-specific. Consequently, more than 75% of cases are diagnosed at an advanced stage (FIGO III/IV). Despite some improvement of median survival rates due to the development of primary surgical procedures and chemotherapy protocols, the percentage is relatively constant around 30%. Alternatively, women diagnosed in the first stages of disease will not only undergo much

Manuscript received: 21.12.2012

Received in revised form: 20.01.2013

Accepted: 21.01.2013

Address for correspondence: anitamercea@yahoo.com

less aggressive surgery, but will also have a 90% 5-year survival rate and better quality of life. Unfortunately, the high percentage of patients diagnosed at advanced stages emphasizes the lack of efficiency of pelvic examination and imaging techniques in confirming incipient disease and calls for more advanced diagnostic tools.

There are two major diagnostic challenges when an ovarian mass is detected: the determination of malignancy and the evaluation of the tumor extent (staging). Diagnostic studies that allow accurate confirmation of benignity might reduce unnecessary surgery. Diagnostic studies that allow accurate cancer staging would help determine surgical and chemotherapeutic planning. Bimanual pelvic examination and serum CA 125 levels have failed to allow consistent detection of ovarian malignancy. Because the sensitivities of these techniques are often below 50% [3-5], imaging modalities, particularly ultrasonography (US), computer tomography (CT) and magnetic resonance (MR) imaging have become indispensable.

The recent introduction of HE4 and ROMA score for predicting the risk of ovarian cancer has offered new perspectives in the early diagnosis of this disease and post-chemotherapy monitoring of response. The ROMA is a simple scoring system that combines CA125 and HE4 values and shows good diagnostic performance for the detection of epithelial ovarian cancer in postmenopausal women, but not in premenopausal women. Moreover, the dual marker combination does not show better performance than HE4 alone [6]. The lack of statistically-significant results in premenopausal women leaves a large population of patients for which this biochemical screening method is not efficient.

Ultrasonography is a well-established diagnostic modality for the preoperative evaluation of pelvic masses, regardless of the patient's hormonal status. Subjective evaluation (pattern recognition - presence of septae, solid parts, papillae, multilocular cysts) of the gray-scale ultrasound image by an expert is accurate with regard to malignancy in more than 90% of cases [7]. Color Doppler and Power Doppler ultrasound can be used to detect neovascularization in malignant lesions [8], and Doppler examination may add information to the gray-scale image. The combined use of morphological parameters and vascularity described by Doppler examination improves the ability to diagnose ovarian cancer to a certain extent (some overlap exists between benign/malignant tumors) [9]. Even with the best technology, only the macrovessel network (between 100-200 μm) can be visualized.

In order for a tumor to develop from a few millimeters to several centimeters, it must develop a neovascular network to sustain its growth, which consists of abnormal vessels. They are large and irregular in caliber, have abnormal branching points and blind-ending pouches. Microbubble contrast agents are approximately one half to one third the size of an erythrocyte and therefore

can course through these capillaries [10].

Ultrasonography enhanced with intravascular contrast agents allows detection of signals from blood vessels with diameters of less than 40 microns [11]. Dedicated ultrasound technology has been developed to optimize the use of ultrasound contrast media in gynecology, e.g. contrast-tuned imaging (CnTI) technology using the second-generation contrast agent SonoVue, Bracco [12]. Depiction of tumour neovascularity at the capillary level can be accomplished with the use of contrast-enhanced ultrasonography. Several studies have concluded that significant differences can be detected in several contrast kinetic enhancement patterns [12-15].

Although the method is currently used with great success in gastroenterology, urology and senology, its validation in gynecology is still in its early phases. Taking into consideration that the method is minimally invasive and much less costly than CT/MRI imaging, demonstrating its utility in gynecologic oncology would be a big step in preoperative evaluation of these cases.

The objective of our current research is to discuss and illustrate the use of contrast-enhanced ultrasound in evaluating ovarian tumors compared to conventional ultrasound, Doppler ultrasound and histopathological analysis and suggest how this technique may best be used to distinguish benign from malignant ovarian masses.

Patients and method

Patients were recruited from October 2011 to December 2012. The participating centers were The Oncology Institute "Prof. Dr. I. Chiricuță" Cluj-Napoca, The Obstetrics and Gynecology Clinic II "Dominic Stanca" for recruiting and operative treatment of patients, and the ultrasound examinations were conducted within the Regional Gastroenterology and Hepatology Institute "Prof. Dr. Octavian Fodor".

The inclusion criteria were: ultrasound or clinical diagnosis of a pelvic mass of unknown etiology with surgical indication; age 18 years or more and written informed consent to participate in the study. Pregnant or nursing patients and patients with any contraindication to the use of SonoVue contrast medium were not eligible. Examples of contraindications to the use of SonoVue are cardiac insufficiency, severe lung disease, severe cardiac arrhythmia, recent myocardial infarction, unstable angina pectoris, acute endocarditis, artificial heart valves, acute systemic inflammation or sepsis, hypercoagulability, recent thrombo-embolic disease and terminal renal or liver disease. The study protocol was approved by the local ethics committees.

Each patient was examined as described below: before the US examination, a medical history was taken. A woman was considered to be postmenopausal if she reported a period of at least 12 months of amenorrhea.

All ultrasound examinations were performed using

a General Electric Logiq7 BT07 system with a trans-abdominal 4C probe with a frequency of 1.5-5 MHz. A gray-scale, Color Doppler and Pulse Doppler ultrasound examination were performed using a standardized examination technique. The following parameters were assessed: location of the lesion, size, unilateral or bilateral mass, presence of ascites and/or fluid in the pouch of Douglas, type of mass (cystic, unilocular, multilocular, solid), presence of papillary projections, septae. After the assessment of the adnexal mass, a general abdominal ultrasound was carried out to exclude any other intra-abdominal lesions and evaluate the extent of disease.

Contrast examination was carried out after completion of the gray-scale and Doppler ultrasound examinations. The same settings were used for all contrast examinations (mechanical index between 0.09-0.11, focal point just beneath the area of interest, PRF of 4 KHz). Each patient received 1 injection of 1.6 ml of SonoVue, Bracco contrast medium in bolus via an indwelling catheter placed in an antecubital vein. The examination was performed on the section through the pelvic mass that was judged subjectively by the ultrasound examiner to contain the most vascularized solid parts of the tumor at Doppler examination. A 3-minute recording for time intensity analysis was started immediately after completion of the injection. All contrast clips were stored electronically for later analysis using dedicated software. Quantitative analysis was comprised by automatic rendering of the Time Intensity Curve (TIC) from the regions of interest (ROI) localized within the tumor. We used the postprocessing software SonoLiver (Bracco, Italy). The following perfusion parameters were calculated: Rise Time – RT, Time To Peak – TTP, Mean Transit Time – MTT. With the use of dedicated software, the following steps were taken to render the TIC: contouring of the examination region of the tumor, delineation of the Region of Interest. If the tumor was predominantly solid, the area of interest was traced around the periphery of the pelvic mass. In case of complex cystic masses, the ROI was

centered on the solid intratumoral component of the septae. Due to the reduced influence of respiratory movement on the pelvis, processing of the clips did not require the use of a movement compensation algorithm. The results of both unenhanced and contrast-enhanced examinations were compared with those of the histological examination of the respective surgical specimens. Staging of the malignant tumors was done by the curing physicians in accordance with the classification system recommended by the International Federation of Gynecology and Obstetrics [16].

Results

The results of this initial analysis are presented as a means of proving that the method is feasible, has no adverse effects for the patients and offers a much more detailed and significant imaging characterization than conventional and Doppler ultrasound in patients with pelvic masses of uncertain etiology.

During the period of time stated above, 6 patients were examined and included in the research. No adverse effects of SonoVue occurred. Given the descriptive nature of this initial research, we present below the clinical characteristics and ultrasound parameters from these cases.

The mean age of the patients was 49, and three cases were confirmed to be malignant ovarian tumors, while the other three were benign masses. The general characteristics of the cases are presented in Table I.

The grey-scale ultrasound found one solid tumor and 5 cystic either unilocular or multilocular masses. Presence of septae or intratumoral vegetations is comprised in table II.

The presence of Doppler signal and Pulse-Doppler characteristics are presented in Table III.

Results of the quantitative analysis of the Time-Intensity curves are presented in Table IV.

Below we present images acquired during post-processing of the contrast-enhanced ultrasound images and the steps required to analyze time intensity curves as presented in the patients and method section.

Table I. Clinical characteristics.

| | Age | Parity | Hormonal status | Personal history | Histology | CA 125 value U/ml |
|--------|-----|--------|-----------------|---|--|-------------------|
| Case 1 | 52 | 2 | Postmenopausal | Hypertension | Benign cystadenoma | 34 |
| Case 2 | 47 | 2 | Premenopausal | | Epithelial (Clear cell) carcinoma FIGO IIC | 586 |
| Case 3 | 43 | 1 | Postmenopausal | Ovarian cyst, uterine fibroma, hypertension | Epithelial (Clear cell) carcinoma FIGO IA | 47 |
| Case 4 | 49 | 0 | Postmenopausal | | Benign cystadenofibroma | 7 |
| Case 5 | 44 | 2 | Premenopausal | | Benign ovarian fibroma | 22 |
| Case 6 | 59 | 1 | Postmenopausal | | Epithelial (Serosus) carcinoma FIGO IIC | 420 |

Table II. Gray-scale ultrasound characteristics.

| | Unilateral/Bilateral | Ascites | Maximum diameter | Type of tumour | Solid component | Presence of septae |
|--------|----------------------|---------|------------------|---------------------|-------------------------------------|--------------------|
| Case 1 | Bilateral | no | 40 mm | cystic | no | no |
| Case 2 | Bilateral | yes | 190 mm | cystic | solid tissue, papillary projections | yes |
| Case 3 | Unilateral | no | 95 mm | cystic | papillary projections | no |
| Case 4 | Unilateral | no | 100 mm | cystic | papillary projections | no |
| Case 5 | Unilateral | no | 70 mm | solid | solid tissue | no |
| Case 6 | Bilateral | yes | 123 mm | cystic multilocular | solid tissue | yes |

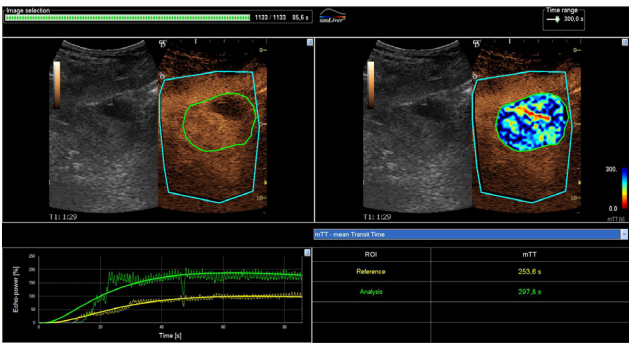


Image 1. Case 1.

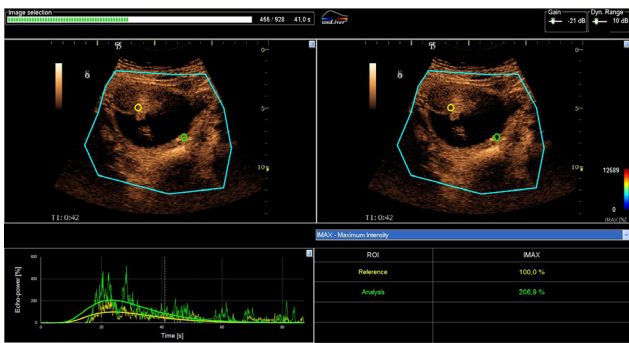


Image 4. Case 4.

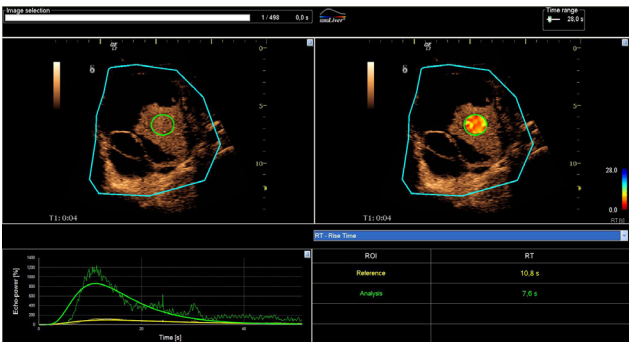


Image 2. Case 2.

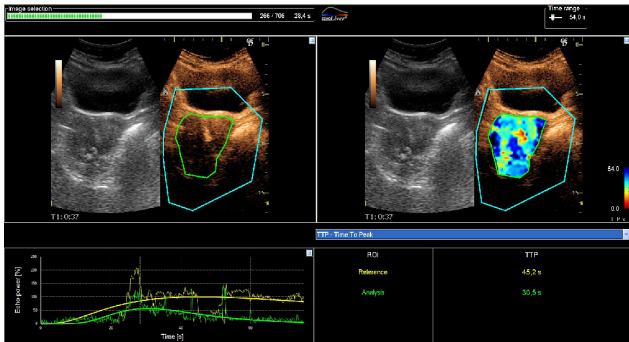

Image 5. Case 5.

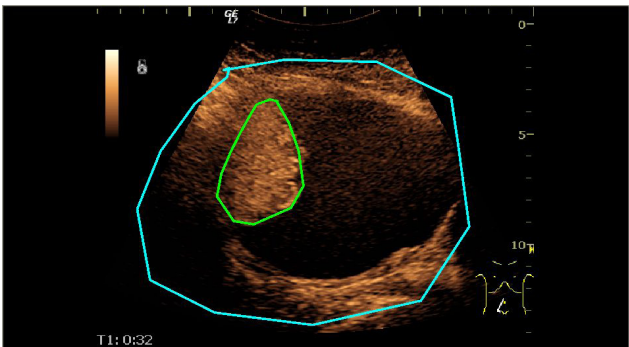


Image 3. Case 3 - Delineation of the Region of Interest.

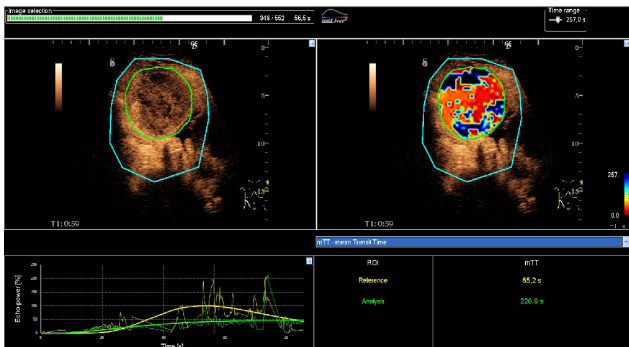


Image 6. Case 6.

Table III. Pulse Doppler characteristics.

| | Presence of signal in papillation, if present | Presence of signal in solid parts | Resistivity index - RI | Pulsatility index - PI |
|--------|---|-----------------------------------|------------------------|------------------------|
| Case 1 | no | no | 0.68 | 0.73 |
| Case 2 | yes | yes | 0.58 | 0.88 |
| Case 3 | yes | yes | 0.65 | 2.61 |
| Case 4 | yes | no | 0.83 | 1.46 |
| Case 5 | no | yes | 0.45 | 0.71 |
| Case 6 | yes | yes | 1.00 | 4.38 |

Table IV. Quantitative contrast characteristics.

| | Rise Time - RT Reference/Analysis | Time to Peak - TTP Reference/Analysis | Mean Transit Time - MTT Reference/Analysis |
|--------|-----------------------------------|---------------------------------------|--|
| Case 1 | 63.11/58.10 | 69.77/62.56 | 253.63/297.84 |
| Case 2 | 10.76/7.61 | 13.40/10.99 | 26.89/16.43 |
| Case 3 | 8.01/18.04 | 19.92/31.57 | 21.75/39.40 |
| Case 4 | 14.83/14.29 | 23.97/23.32 | 31.73/30.60 |
| Case 5 | 39.08/18.22 | 45.17/30.47 | 121.98/39.24 |
| Case 6 | 29.46/67.73 | 53.25/77.50 | 65.18/220.94 |

Parameter definition: RT - Rise Time, TTP - Time To Peak, mTT - mean Transit Time; Unit definition: [%] = percent, [s] = second, NaN = Not a Number, +Inf. = Positive Infinity, -Inf. = Negative Infinity.

Discussion

The cases in this article were studied in order to assess the feasibility and utility of contrast-enhanced ultrasound in evaluating pelvic masses of uncertain etiology. Given the small sample size in this early stage of our research, drawing statistical conclusions is not justified. However, we found a slight tendency toward difference between benign and malignant tumors regarding contrast parameters. Vascular dynamics seems to be different in that malignant masses had a higher blood-flow speed and shorter contrast acquisition times. To confirm these results we need to further expand our study population to a statistically significant size. We have currently reached a number of 15 patients but including all of them in this article was not possible due to technical restraints (unavailable histological result- patients were operated on in the last 40 days - or time-intensity curve postprocessing). To the best of our knowledge there are only a few published studies describing the analysis of time intensity curves in adnexal masses after injection of ultrasound contrast, and their results are controversial [13-15]. On the other hand, most of the other published studies also evaluate the Area Under the Curve (AUC) which seems to be the most significant parameter for the differential diagnosis between benign and malignant tumors. We have included this parameter to some of our patients and expect to be able to calculate its statistical significance.

The role of the CnTI SonoVue technique in gynecological clinical practice is still uncertain. SonoVue is a safe drug that has been used for diagnostic purposes in large series of patients but its acceptability remains unknown. Images are of great quality, the technique does not involve patient irradiation, but it is still a rather expensive drug that involves an intravenous injection and the quantitative analysis of the clips is time-consuming [17].

Conclusions

Microbubble-enhanced ultrasonography can improve the preoperative evaluation of pelvic masses by early detection of tumour microvasculature. Adding contrast to conventional ultrasound examinations in selected cases offers more conclusive information about the nature of vascularization within the tumour and therefore the benignity or malignancy of the mass. At the same time, it does not expose the patient to unnecessary radiation and offers better cost-efficiency conditions than imaging investigations such as CT/MRI. It must also be acknowledged that biochemical investigations, of which HE4 seems to be the most sensitive and specific, are also important tools in preoperative evaluation of suspect pelvic masses and need to be included in a diagnostic protocol.

References

1. Schorge JO, Schaffer JJ, Halvorson LM, Hoffman BL, Bradshaw KD, Cunningham FG. Williams Gynecology. McGraw-Hill, 2008.
2. Dutta S, Wang FQ, Fleischer AC, Fishman DA. New Frontiers for Ovarian Cancer Risk Evaluation: Proteomics and Contrast-Enhanced Ultrasound. American Journal of Roentgenology, 2010; 194:349-354.
3. Taylor K, Schwartz P. Screening for ovarian cancer. Radiology, 1994; 192:1-10.
4. Creasman W, Disaia P. Screening in ovarian cancer. Am J Obstet Gynecol, 1991; 165:7-10.
5. Droegemueller W. Screening for ovarian carcinoma: hopeful and wishful thinking. Am J Obstet Gynecol, 1994; 170:1095-1098.
6. Montagnana M, Danese E, Ruzzenente O, et al. The ROMA (Risk of Ovarian Malignancy Algorithm) for estimating the risk of epithelial ovarian cancer in women presenting with pelvic mass: is it really useful? Clin Chem Lab Med, 2011; 49(3):521-525.
7. Valentin L. Prospective cross-validation of Doppler ultrasound examination and gray-scale ultrasound imaging for discrimination between benign and malignant pelvic masses. Ultrasound Obstet Gynecol, 1999; 14:273-283.
8. Tekay A, Jouppila P. Validity of pulsatility and resistance indices in classification of adnexal tumors with transvaginal color Doppler ultrasound. Ultrasound Obstet Gynecol, 1992; 2:338-344.
9. Alcazar JL, Rodriguez D. Three-dimensional power Doppler vascular sonographic sampling for predicting ovarian cancer in cystic-solid and solid vascularized masses. J Ultrasound Med. 2009; 28:275-281.
10. Fleischer AC, Lyshchik A, Andreotti RF, Hwang M, Jones HW, Fishman DA. Advances in sonographic detection of ovarian cancer: depiction of tumor neovascularity with microbubbles. AJR, 2010; 194:343-348.
11. Becker H, Burns PN. Handbook of contrast echocardiography. LV function and myocardial perfusion. Springer Verlag, Heidelberg, 2000; 25-26.
12. Testa AC, Ferrandina G, Fruscella E, et al. The use of contrasted transvaginal sonography in the diagnosis of gynecologic diseases: a preliminary study. J Ultrasound Med, 2005; 24:1267-1278.
13. Orden MR, Jurvelin JS, Kirkinen PP. Kinetics of a US contrast agent in benign and malignant adnexal tumors. Radiology, 2003; 226:405-410.
14. Marret H, Sauget S, Giraudeau B, et al. Contrast-enhanced sonography helps in discrimination of benign from malignant adnexal masses. J Ultrasound Med, 2004; 23:1629-1642.
15. Fleischer AC, Lyshchik A, Jones HW Jr, et al. Contrast-enhanced transvaginal sonography of benign versus malignant ovarian masses: preliminary findings. J Ultrasound Med, 2008; 27:1011-1021.
16. Sheperd JH. Revised FIGO staging for gynecological cancer. Br J Obstet Gynaecol, 1989; 96:889-892.
17. Testa AC, Timmerman D, Van Belle V, et al. Intravenous contrast ultrasound examination using contrast-tuned imaging (CnTI) and the contrast medium SonoVue for discrimination between benign and malignant adnexal masses with solid components. Ultrasound Obstet Gynecol, 2009; 34:699-710.